



Patient

NHS No

D.O.B.

Patient Ref

Reason

Varicose vein

Outcome

Incompetence

	Right		Left	
Deep Veins	Patency	Competency	Patency	Competency
Common Iliac Vein				
External Iliac Vein				
Internal Iliac Vein				
Common Femoral Vein	Widely Patent	Competent		
Profunda Vein				
Superficial Femoral Vein				
Popliteal Vein	Widely Patent	Competent		
Posterior Tibial Vein				
Anterior Tibial Vein				
Peroneal Vein				
Soleal Vein				
Gastrocnemius	Widely Patent	Incompetent (medial)		
Superficial Veins				
Saphenofemoral Junction	Widely Patent	Competent		
L Saphenous Vein Above	Widely Patent	Competent		
L Saphenous Vein Below	Widely Patent	Competent		
Vein of Giacomini	Widely Patent	Competent		
Saphenopopliteal Junction	Not Identified			
S Saphenous Vein	Widely Patent	Isolated Incompetence		
Evidence of D.V.T.				
Above the knee	No			
Popliteal	No			
Below the knee				

Notes**RIGHT LOWER LIMB VENOUS DUPLEX ASSESSMENT**

Iliac veins not viewed. Flow in the common femoral vein is phasic with respiration and a normal response on Valsalva manoeuvre, suggesting proximal vein patency. Common femoral and popliteal veins are widely patent and competent with no evidence of DVT.

Sapheno-femoral junction (SFJ) and long saphenous vein (LSV) appear to be competent. Sapheno-popliteal junction (SPJ) was not identified. Short saphenous vein (SSV) origin is competent and is continuous with a competent vein of Giacomini. The SSV junction with medial gastrocnemius vein appears to be incompetent, rendering the SSV within the proximal calf incompetent. The SSV within the proximal calf is linear, with an incompetent branch leaving the vessel at mid calf, forming the postero-medial varicosities and rendering the distal SSV competent.

Assessed by

Lukasz Koprowski

Checked by



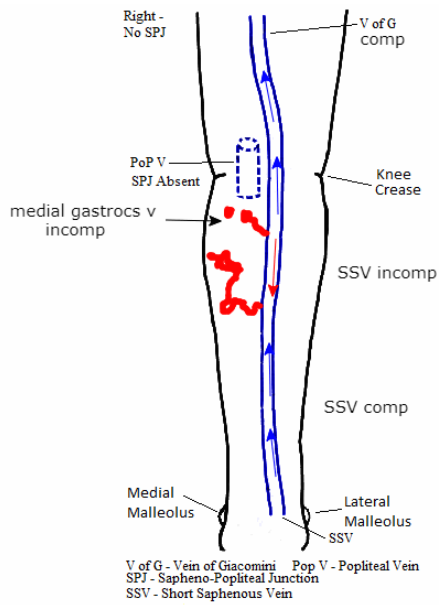
Patient

NHS No

D.O.B.

Patient Ref

Transverse (AP) dimensions of SSV: proximal calf 0.76cm, mid calf 0.6cm.



Assessed by

Lukasz Koprowski

Checked by